Received: 7 October 2020 | Revised: 5 March 2021 | Accepted: 29 March 2021

DOI: 10.1111/tbed.14093

ORIGINAL ARTICLE

Transboundary and Emerging Diseases WILEY

Black rats (*Rattus rattus*) as potential reservoir hosts for Rift Valley fever phlebovirus: Experimental infection results in viral replication and shedding without clinical manifestation

Franziska Stoek[1] | Melanie Rissmann[1,2] | Reiner Ulrich[3,4] | Martin Eiden[1] | Martin H. Groschup[1]

[1]Institute of Novel and Emerging Infectious Diseases, Friedrich-Loeffler-Institut, Greifswald-Insel Riems, Germany

[2]Department of Viroscience, Erasmus MC, Rotterdam, Netherlands

[3]Department of Experimental Animal Facilities and Biorisk Management, Friedrich-Loeffler-Institut, Greifswald-Insel Riems, Germany

[4]Faculty of Veterinary Medicine, Institute of Veterinary-Pathology, Universität Leipzig, Leipzig, Germany

Correspondence
Martin H. Groschup, Institute of Novel and Emerging Infectious Diseases, Friedrich-Loeffler-Institut, Greifswald-Insel Riems, Germany.
Email: martin.groschup@fli.de

Funding information
Deutsche Forschungsgemeinschaft, Grant/Award Number: GR 980/4-1

Abstract

Rift Valley fever phlebovirus (RVFV) is an arthropod-borne virus that can cause severe disease in ruminants and humans. Epidemics occur mainly after heavy rainfall, which leads to a significant increase in the occurrence of RVFV-transmitting mosquitoes. During inter-epidemic periods, the virus is assumed to be maintained between mosquitoes, susceptible livestock and yet unknown wildlife. The widespread rodent *Rattus rattus* (black rat) has been suspected to be involved in RVFV maintenance. In order to elucidate its susceptibility and thus its possible role in the transmission cycle of the virus, an experimental infection study was performed. Black rats were subcutaneously infected with highly virulent RVFV strain 35/74 and euthanized on days 3, 14 and 28 post-infection. Additional black rats served as non-infected contact animals. The infected black rats showed high susceptibility to RVFV infection. Generation of RVFV-neutralizing antibodies was found, and the rats developed viraemias lasting up to 17 days. Viral RNA was found in tissues until the last day of the experiment. However, neither a clinical manifestation nor virus-induced histopathological lesions were observed in any rat. These findings indicate the persistence of RVFV in black rats without affecting the animals. In contact animals, no evidence of horizontal RVFV transmission was found, although the co-housed infected rats showed oral, rectal and conjunctival RVFV shedding. Results of this study point to an involvement of black rats in the RVFV transmission cycle, and further studies are needed to investigate their potential role in the maintenance of the virus.

KEYWORDS

black rat, inter-epidemic cycle, *Rattus rattus*, Rift Valley fever, rodents, virus reservoir

1 | INTRODUCTION

Rift Valley fever phlebovirus (RVFV) is an arthropod-borne virus (arbovirus) belonging to the order Bunyavirales that can cause severe disease in ruminants and humans (Bird et al., 2009). The enveloped RNA virus has a tripartite genome comprising negative-sense large (L) and medium (M) segments and an ambisense small (S) segment, encoding the RNA-depending RNA polymerase, the glycoproteins Gn and Gc, the

[Correction added on 12 July 2021, after first online publication: The copyright line was changed.]

nucleoprotein NP, and the non-structural proteins NSm and NSs. The latter is known to be the major factor of virulence (Pepin et al., 2010).

RVFV was first described in 1931 in Kenya, causing so-called 'abortion storms' with newborn fatality rates of up to 100% in livestock (Daubney & Hudson, 1931). The virus primarily effects ruminants and humans, but a wide range of other vertebrates are also known to be susceptible to RVFV (Olive et al., 2012). Over 40 different mosquito species were found to be naturally infected with the arbovirus (Chevalier et al., 2010; Linthicum et al., 2016). In ruminants, the infection mainly occurs via the bite of RVFV-infected mosquitoes, whereas humans can also become infected through contact with infected animals or their tissues (Chevalier et al., 2010). Humans usually develop a flu-like febrile illness, but in about 1% of patients, severe neurological disorders, blindness or even fatal haemorrhagic fever can occur (Bird et al., 2009). So far, Rift Valley fever (RVF) outbreaks have been restricted to the African continent and the Arabian Peninsula, but sudden outbreaks in distant, previously unaffected areas demonstrate the dissemination potential of the virus (Balkhy & Memish, 2003; Digoutte & Peters, 1989; Freed, 1951; Meegan et al., 1979). The transmission cycle of the virus is divided into an enzootic and an epidemic cycle. The epidemic cycle mainly occurs after heavy rainfall, leading to a significant increase in the mosquito population, which raises the probability of virus transmission between mosquitoes and susceptible hosts. During the enzootic cycle, the virus is believed to be maintained by transovarial transmission (*Aedes* spp.) within the mosquito population and sporadic infections of susceptible livestock and wildlife (Rissmann et al., 2019), but the wildlife contributing to the maintenance of the virus has not yet been identified (Olive et al., 2012). In general, several characteristics are necessary for an animal to serve as viral amplification host: the general susceptibility to the pathogen with the development of a viraemia, but without severe clinical manifestation and a shared habitat with mosquitoes that facilitates the probability of virus transmission (Rodhain, 1998). Although there is evidence of rodents being involved in RVFV maintenance, published data are contradictory and not conclusive. Data indicate that *Arvicanthis niloticus*, *Micaelamys namaquensis* and *Rattus rattus* have the highest probability of being involved in the RVFV transmission cycle and research should be continued (Olive et al., 2012).

Rattus rattus (black rat) is a widespread rodent in Africa, which is also suspected to serve as reservoir for other arboviruses (Diagne et al., 2017). It has been introduced to all regions where RVF epidemics have occurred (Olive et al., 2012). Already during the first described RVF outbreak, black rats were observed to be susceptible to the virus (Daubney & Hudson, 1932). RVFV was detected in brain (Imam et al., 1979) and blood (Youssef & Donia, 2002) of *Rattus rattus* and they were also found to carry RVFV-specific antibodies (Gora et al., 2000; Hoogstraal et al., 1979; Youssef & Donia, 2001). Additionally, a vector–host interaction between mosquitoes and black rats has been demonstrated (Lutomiah et al., 2014). Together, these findings suggest a role of *Rattus rattus* in the virus' ecology. In the past, experimental infection studies with in-bred rats (*Rattus norvegicus*) have shown that rats differ markedly in their susceptibility to RVFV depending on their genetic background (Anderson et al., 1987; Peters & Slone, 1982; Ritter et al., 2000), demonstrating that only a survey of *Rattus rattus* can provide information on their potential role as RVFV amplification hosts. However, only an experimental infection of two black rats has been carried out previously, resulting in the development of viraemia (Hoogstraal et al., 1979).

To elucidate the role of *Rattus rattus* in the RVFV transmission cycle, we performed an experimental infection with black rats. The aim of this study was to investigate their susceptibility to RVFV, the course of an infection and the possibility of virus persistence. Twelve black rats were subcutaneously infected with RVFV strain 35/74, and virus shedding, virus replication in tissue and immune responses were analysed. Three additional black rats served as non-infected contact animals to verify horizontal transmission.

2 | MATERIALS AND METHODS

2.1 | Virus and cell culture

RVFV strain 35/74 (accession number: JF784386-88), recombinantly produced and kindly provided by Jeroen Kortekaas (University of Wageningen, Wageningen Bioveterinary Research, Lelystad, Netherlands), was grown on BHK 21 cells (baby hamster kidney cells, Collection of Cell Lines in Veterinary Medicine, Friedrich-Loeffler-Institut). To determine the virus titre, a 50% Tissue Culture Infective Dose ($TCID_{50}$) assay was used. Serial diluted RVFV 35/74 was added on 90% confluent monolayers of BHK 21 cells. After incubation at 37°C, 5% CO_2 for six days, cells were fixed with neutral buffered formalin and stained with crystal violet and the $TCID_{50}$ was calculated as described by *Spearman and Kärber* (Kärber, 1931).

2.2 | Animals and experimental design

Eighteen adult black rats (*Rattus rattus*, Tilbury strain, *RR1-18*), nine females and nine males, were purchased from Franz-Rainer Matuschka (University of Potsdam, Potsdam, Germany). The rats were kept at biosafety level 3 (BSL-3) containment facilities of the Friedrich-Loeffler-Institut, Insel Riems. Up to three black rats of the same sex were kept together in a cage.

During an adaptation period of one week, blood and swab samples of all rats were tested negative for RVFV by quantitative real-time RT-PCR (qRT-PCR). Additionally, blood samples were tested negative for RVFV-specific antibodies in the serum neutralization test (SNT).

At the start of the experiment, 12 of 18 black rats were subcutaneously infected with 0.25 ml of 1 x 10^5 $TCID_{50}$/ml RVFV 35/74. This viral infection dose was selected based on literature (Anderson et al., 1987; Ritter et al., 2000). The other six rats received 0.25 ml of sterile medium. Three of those six non-infected rats were kept separately as negative controls (*RR16-18*) and the other three rats were

each kept together with two infected rats to determine the possibility of a horizontal infection (contact animals: *RR5*, *RR10 and RR14*).

Blood and oral, conjunctival and rectal swab samples were taken at day post-infection (dpi) 2, 3, 4, 5, 6, 7, 8, 11, 14, 17, 21 and 24. Blood samples were additionally taken at dpi 1 and 28. The body weights were also measured on the sampling days. To minimize the stress for the animals and to facilitate the handling, the rats were anaesthetized by intramuscular injection of tiletamine–zolazepam (Zoletil®, Virbac) before interventions. Furthermore, rats were divided into two groups that were sampled alternately during the first 8 days. All animals were observed daily for behavioural and clinical anomalies.

Four infected rats, one contact animal and one negative control rat each were killed at dpi 3, 14 and 28 (Table S1). The rats were injected with pentobarbital sodium (Release®, WDT-Wirtschaftsgenossenschaft deutscher Tierärzte eG) after anaesthetization and subsequently bled by cardiac puncture. Specimens of livers, lungs, spleens, kidneys, hearts, brains and intestines were collected.

2.3 | Serology

Serology was performed with heat-inactivated sera taken during euthanasia.

Serum samples were tested with the ID Screen® Rift Valley Fever Competition Multi-species ELISA (IDvet) that is based on the RVFV NP. The ELISA was conducted according to the manufacturer's specifications. It verifies the presence of IgG and IgM antibodies without distinguishing between both antibody isotypes.

A serum neutralization test (SNT) was performed as recommended in the OIE Terrestrial Manual (OIE World Organisation for Animal Health, 2012, OIE World Organisation for Animal Health, 2018). Duplicates of diluted sera [1:10–1:2,560] were added to 100 $TCID_{50}$ of RVFV 35/74 and 3 x 10^5 BHK 21 cells/ml. After incubation for 6 days at 37°C and 5% CO_2, cells were fixed with neutral buffered formalin and stained with crystal violet and neutralizing doses of 50% (ND_{50}) were calculated.

To identify antigen-specific IgG antibodies, Nunc MaxiSorp® flat-bottom plates (Thermo Fisher Scientific) were coated with 4 μg/ml recombinant bacterially expressed antigens NP, Gn, Gc, NSm and NSs. After incubation (4°C) overnight, plates were washed three times with phosphate-buffered saline and 0.1% Tween-20. To block non-specific bindings, 10% skim milk was added and incubated (37°C) for 1 hr. After washing, skim milk (2%) diluted samples [1:25] were added and likewise incubated. Following washing, 15 μg/ml goat anti-rat IgG antibody (dianova GmbH) was added and incubated. Plates were washed, and a 1:5,000 diluted donkey anti-goat-HRPO antibody (dianova GmbH) was added and also incubated as before. After washing, 2,2′-azino-di-(3-ethylbenzothiazoline sulphonic acid; ABTS; F. Hoffmann-La Roche AG) was added and incubated (room temperature, 30 min) in the dark. Finally, the reaction was stopped with the addition of 1% sodium dodecyl sulphate (SDS). Reading was performed at 405 nm.

2.4 | Detection of RVFV-specific RNA

RNA was extracted from blood cruor, swab medium and tissues using the NucleoMag® VET kit (MACHEREY-NAGEL GmbH & Co. KG) for a magnetic-bead based isolation of viral RNA, according to the manufacturer's recommendations. Prior to extraction, an MS2 bacteriophage was added to each sample as an internal extraction control (Ninove et al., 2011). The presence of RVFV-derived RNA was analysed in a qRT-PCR (Bird et al., 2007) using the QuantiTect® Probe RT-PCR Kit (Qiagen) and quantified with a synthetic calibrator RNA (Jackel et al., 2013). Samples containing more than 1 copy/μl of RVFV-specific RNA were considered positive (Bird et al., 2007).

2.5 | Quantification of viral loads

A $TCID_{50}$ assay of all samples tested positive by qRT-PCR was performed on BHK 21 cells in a fourfold determination. The samples were diluted from 10^{-1} to 10^{-5}, and following steps were performed as described before. RVFV 35/74 was used as positive control.

2.6 | Next-generation sequencing

Next-generation sequencing (NGS) was conducted to verify whether changes in the viral genome have occurred in the rats. Extracted RNA of the lungs with the highest viral RNA load in qRT-PCR (*RR8*) was used to create a DNA library with the Illumina MiSeq System (Illumina, Inc.; Wylezich et al., 2018). The DNA library was sequenced with the MiSeq Reagent Kit v3 (600-cycles; Illumina, Inc.). Sequences were assembled from RVFV-assigned and unclassifiable reads using 454 Software Suite v3.0 (Hoffmann-La Roche AG). The analysis of the sequences was performed with MegaBLAST (blast 2.6.0, build Dec 7 2016 14:50:34).

2.7 | Necropsy, histopathology and immunohistochemistry

Necropsy was performed in a BSL-3 safety cabinet. Specimens from liver, lungs, spleen, kidney, heart, brain and intestine were fixed in 4% neutral buffered formaldehyde, processed, embedded in paraffin wax, sectioned at 2–4 μm thickness and stained with haematoxylin and eosin (HE). Slides were assessed for histopathological lesions using a Zeiss Axio Imager A1 microscope (Carl Zeiss Microscopy).

Immunohistology was performed with the avidin–biotin–peroxidase complex method (ABC, Elite PK6100; Vector Laboratories) with 3-amino-9-ethylcarbazole (AEC, Dako) as chromogen and haematoxylin counterstain. The primary antibody used for the detection of RVFV NP was a heat-inactivated serum of a sheep immunized with RVFV MP12-strain NP (internal code: S24NP) in a dilution of 1:4,000. RVFV MP12-strain-infected and uninfected

Vero 76 cell pellets served as positive and negative controls, respectively. The distribution of the RVFV antigen was semiquantitatively assessed for each organ on a 0–3 scale as follows: 0 = no viral antigen, 1 = focal or oligofocal, 2 = multifocal and 3 = confluent to diffuse immunoreactive cells.

3 | RESULTS

3.1 | Clinical assessment

Throughout the experiment, the rats showed no clinical signs after infection with RVFV 35/74 and their weights remained constant (Figure S2).

3.2 | Serology

In the ID Screen® ELISA, no antibodies against RVFV were found at dpi 3. In contrast, at dpi 14 and 28, antibodies were detectable in all sera of infected animals and immune responses increased from dpi 14 to 28 (Figure 1a). In sera of contact animals (dpi 3, 14 and 28), no seroconversion was detected.

Generation of RVFV-neutralizing antibodies was found in all infected rats from dpi 14, and ND_{50} values increased during the course of the experiment (Figure 1b). No generation of neutralizing antibodies was detected in contact animals.

An increase in RVFV-specific antibodies from dpi 14 was also detected in the indirect IgG ELISA. Comparison of antigen-specific immune responses revealed highest immune responses against NP, followed by Gn and NSm. An increase in antibodies against NSs was detectable, but the mean optical density (OD) at dpi 28 remained below OD values of NP, Gn and NSm at both dpi 14 and 28. Against Gc, no antibody generation was observed (Figure 2). Sera from contact animals showed no increase in RVFV antibodies.

3.3 | Detection of RVFV-specific RNA and quantification of viral loads

By qRT-PCR, the presence of viral RNA in blood was observed between dpi 2 and 21, with a peak of the mean viral RNA load between dpi 5 and 7 (Figure 3a). The first evidence of RVFV-specific RNA in blood cruor (4.96 copies/µl, *RR9*, Figure S3) was found at dpi 2. At dpi 5, the highest RNA load (56,084 copies/µl, *RR12*) was detected. One rat still showed evidence of viral RNA in blood (12.72 copies/µl, *RR15*) at dpi 21. In blood cruor of all eight rats that were kept longer than dpi 3, the presence of viral RNA was observed, whereas no RVFV-specific RNA was detected in blood of animals euthanized at dpi 3 and in blood of contact animals.

In the $TCID_{50}$ assay, RVFV replication was detected in blood between dpi 4 (up to 1,778 $TCID_{50}$/ml, *RR9*) and dpi 14 (316.23 $TCID_{50}$/ml, *RR9*), with the highest viral load found at dpi 5 (10,000 $TCID_{50}$/µl, *RR15*; Figure 3b). In all animals that showed evidence of viraemia in qRT-PCR, replicable virus was also detected.

Examination of swab samples in qRT-PCR revealed oral, conjunctival and rectal RVFV shedding of infected black rats (Figure 4a). Oral shedding was detected in all eight rats kept longer than dpi 3, while seven of these rats showed rectal virus shedding. Conjunctival shedding was detected in five animals. First evidence of shedding was detected in an oral swab sample at dpi 4. Oral shedding peaked at dpi 8 (up to 15,154 copies/µl, *RR9*) and lasted until the last sampling at dpi 24. The first positive rectal swab was

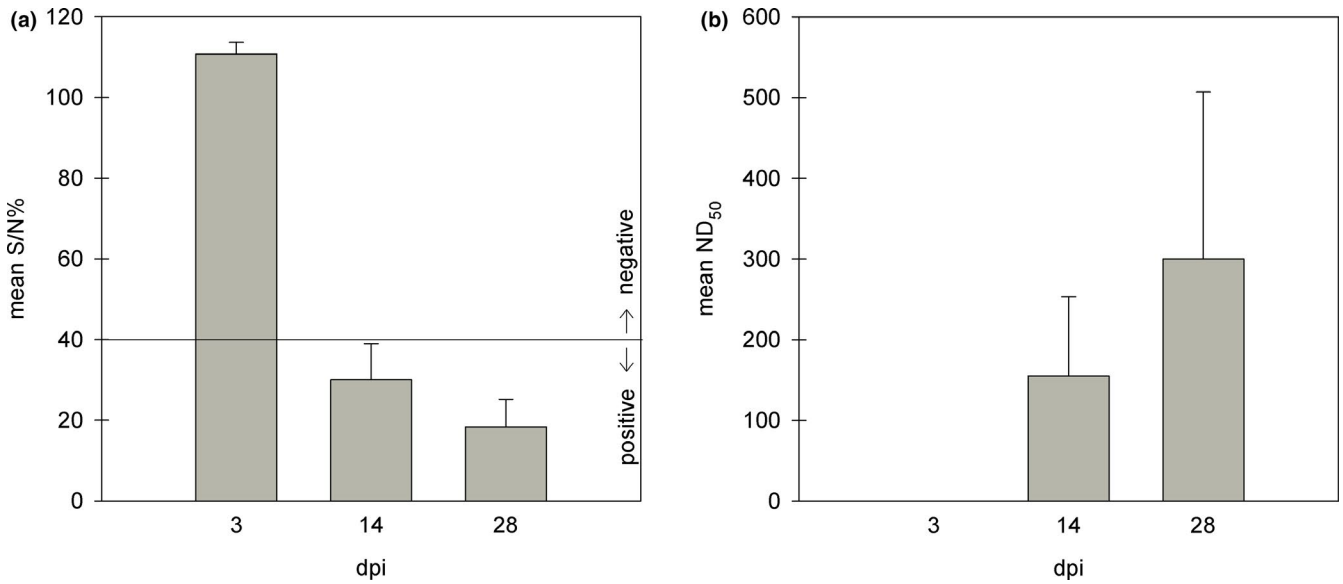

FIGURE 1 Serology. Mean immune responses of the four tested rats per dissection day with corresponding standard deviation. Contact animals showed no seroconversion. (a) Competition ELISA. The cut-off is indicated by the black line. (b) Serum neutralization test (SNT). Neutralizing titres above 1:10 were detected

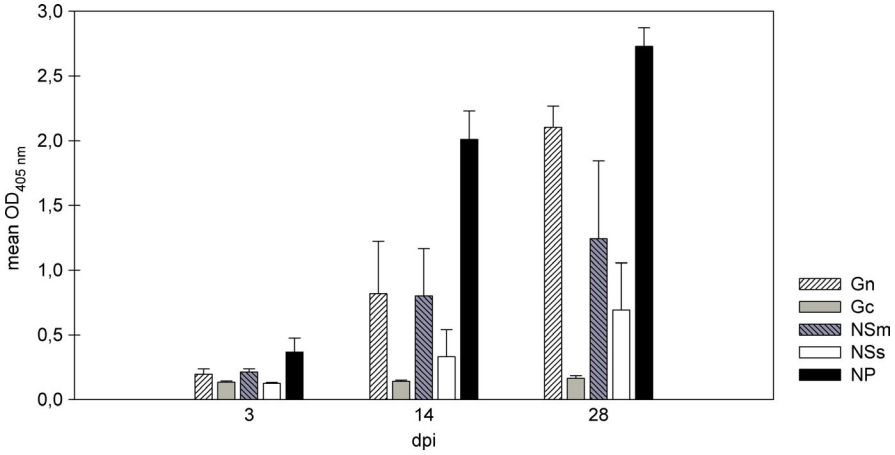

FIGURE 2 Antigen-specific indirect IgG ELISA. Mean immune responses against Gn, Gc, NSm, NSs and NP of the four tested rats per dissection day with corresponding standard deviation. Contact animals showed no seroconversion

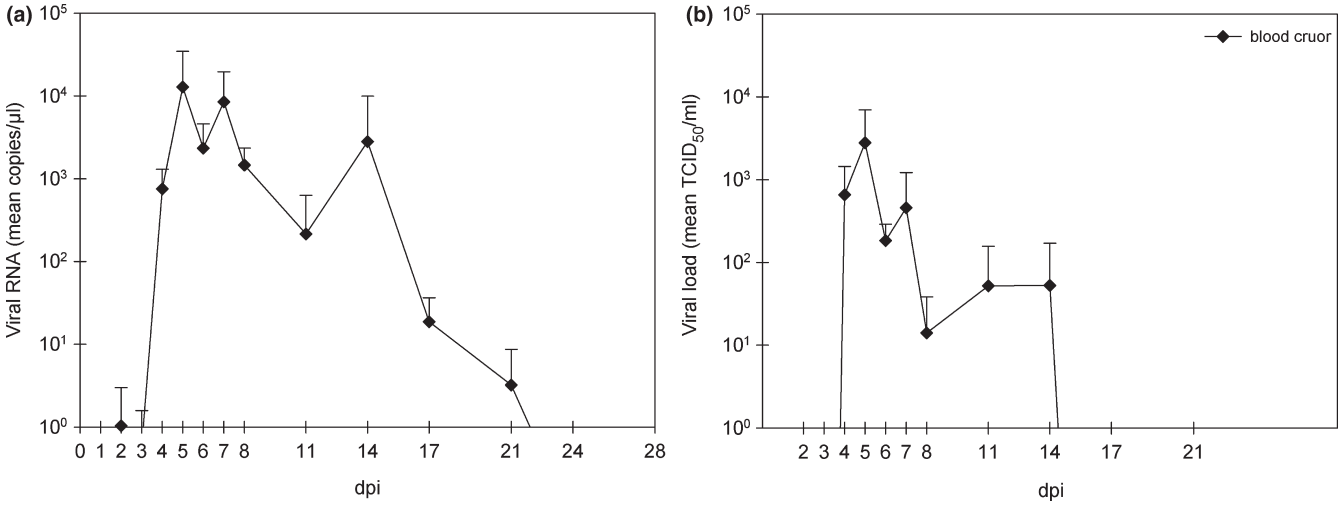

FIGURE 3 Viraemia. Only the sampling days are displayed as a number on the x-axis. Contact animals showed no evidence of RVFV infection. (a) qRT-PCR. Mean detected viral RNA in blood cruor per dpi with corresponding standard deviation. (b) Quantification of viral loads. Mean detected infectious doses in blood cruor per dpi with corresponding standard deviation. Only samples positive by qRT-PCR were analysed

found at dpi 6. Rectal shedding also lasted until dpi 24 and peaked at dpi 8 (up to 198.51 copies/µl, *RR9*) and 21 (up to 379.10 copies/µl, *RR12*). In conjunctival swabs, viral RNA was detected between dpi 8 and 14 with the highest mean RNA load at dpi 8 (up to 64.71 copies/µl, *RR9*). Within an animal, oral, rectal and conjunctival RVFV shedding mostly showed coherent courses (Figure S3). Recurrent shedding was observed in three rats. In swab samples of contact animals, no RVFV-specific RNA was found.

Replicable RVFV was found in all three swab types taken (Figure 4b). In oral swabs, virus was found at dpi 6, 11 and 14. The highest viral load was detected in oral swabs at dpi 6 and 11 (316.23 $TCID_{50}$/ml, *RR13*, *RR6*). In rectal swabs, virus replication was detected at dpi 8 (56.23 $TCID_{50}$/ml, *RR8*), while in conjunctival swabs, evidence of RVFV replication was found in a swab at dpi 14 (56.23 $TCID_{50}$/ml, *RR13*).

With the exception of one rat (*RR2*), RVFV-specific RNA was found in tissues of all infected animals and it was detected in all seven examined tissues (Figure 5).

In livers, highest RNA loads were found at dpi 3 (up to 9,762 copies/µl, *RR3*) and decreased during the experiment (Figure 6). In the other extracted tissues, most viral RNA was detected at dpi 14. Highest RNA loads were measured in lungs (up to 5,000,534 copies/µl, *RR8*), followed by kidneys (up to 202,484 copies/µl, *RR8*) and intestines (up to 55,883 copies/µl, *RR8*). In spleens, viral RNA loads of up to 6,700 copies/µl (*RR9*) were observed and up to 4,676 copies/µl and 3,284 copies/µl (*RR9*) were detected in hearts and brains. At dpi 28, most RVFV-specific RNA was found in a kidney (6,032 copies/µl, *RR13*). In tissues of contact animals, only the intestine of one animal (5.44 copies/µl, *RR10*) showed evidence of RVFV RNA.

The $TCID_{50}$ assay of tissue samples revealed the presence of replicable RVFV in livers, lungs, spleens and kidneys, whereas for hearts, brains and intestines, no virus replication was observed (Figure 7). At dpi 3, replicable virus was only detected in livers. At dpi 14, all four infected rats had detectable viral loads in livers and lungs and one animal additionally showed evidence of replicable RVFV in spleen and kidney. At dpi 28, the presence of replicable virus was detected in the lungs of one rat. Highest viral loads in tissues were found at dpi 14 in lungs and liver of an animal (Table 1A).

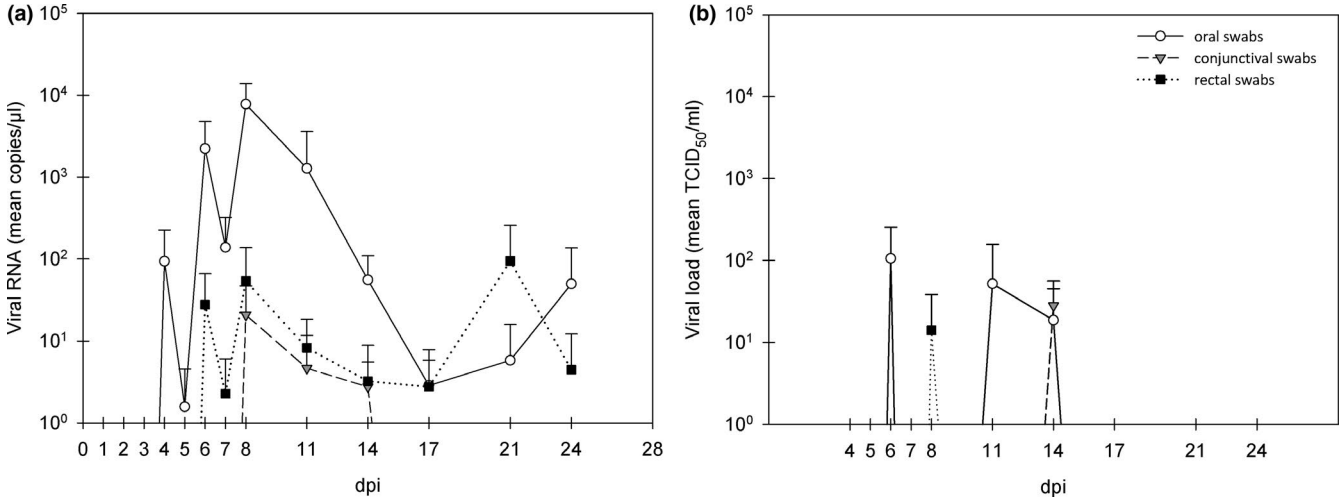

FIGURE 4 Shedding. Only the sampling days are displayed as a number on the x-axis. Contact animals showed no evidence of virus shedding. (a) qRT-PCR. Mean detected viral RNA in swabs per dpi with corresponding standard deviation. (b) Quantification of viral loads. Mean detected viral loads in swabs per dpi with corresponding standard deviation. Only samples positive by qRT-PCR were analysed. Detectable viral loads were found only in a single rectal and conjunctival swab

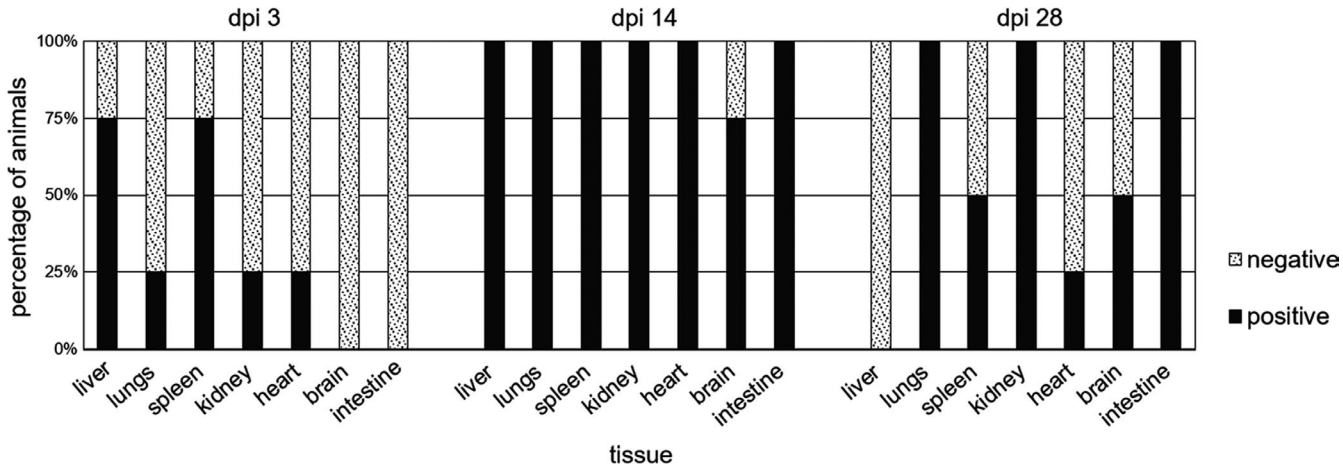

FIGURE 5 Percentage of animals per tissue tested positive by qRT-PCR. Contact animals are not included

The qRT-PCR-positive intestine of the contact animal (*RR10*) showed no evidence of replicable RVFV.

3.4 | Sequence analysis

The sequencing resulted in 2 x 1.06 x 10^6 reads, and results of the MegaBLAST analysis revealed no genomic changes of RVFV 35/74 in the rats.

3.5 | Necropsy, histopathology and immunohistochemistry

Necropsy revealed a variable degree of poorly collapsed lungs with multifocal to coalescing white nodules interpreted as foam cell granulomas in most rats including non-infected controls (Figure S4). Macroscopic lesions typical for RVF were absent.

Histopathology demonstrated a variable mild to severe, multifocal, perivascular, subacute, lymphohistiocytic interstitial pneumonia associated with alveolar oedema and multifocal, intra-alveolar accumulations of hyperplastic, foamy alveolar macrophages and cholesterol clefts in nearly all rats including non-infected controls (Figure 8a,c). A mild, focal, subacute, lymphohistiocytic and necrotizing hepatitis with some neutrophils was observed in a single RVFV-infected rat (*RR1*) at dpi 3, only. The other histopathologically assessed organs revealed no or only minor findings not related to the RVFV infection.

Immunohistochemistry highlighted a much more widespread distribution of RVFV NP antigen as compared to the lesions assessed in the HE-stained sections. At dpi 3, 50% of the RVFV-infected rats displayed few individual pan-cytoplasmatically RVFV-positive hepatocytes without associated lesions (Table 1B). The maximum of virus

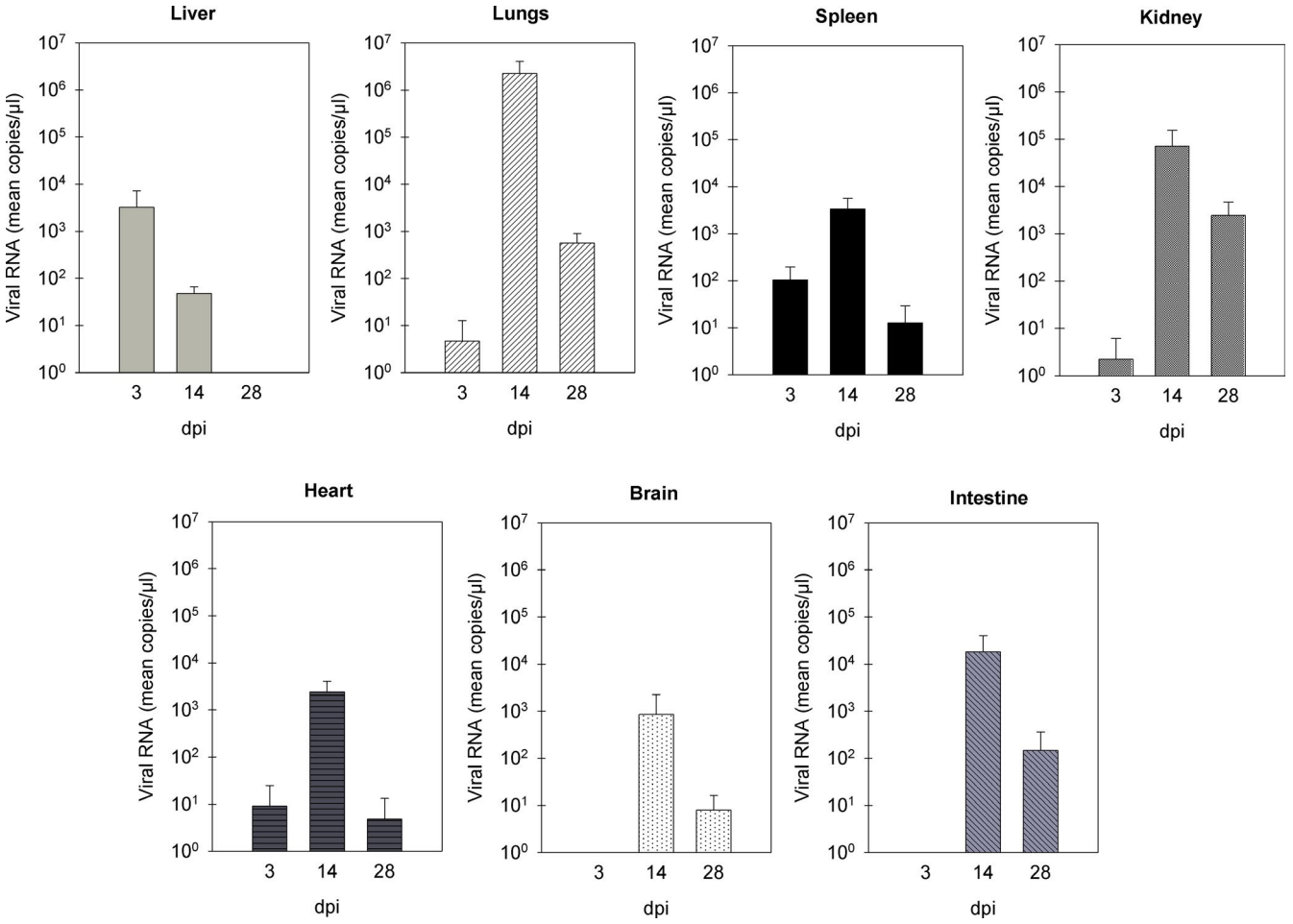

FIGURE 6 Mean detected viral RNA (qRT-PCR) in tissues of the four tested rats per dissection day with corresponding standard deviation. Contact animals are not included

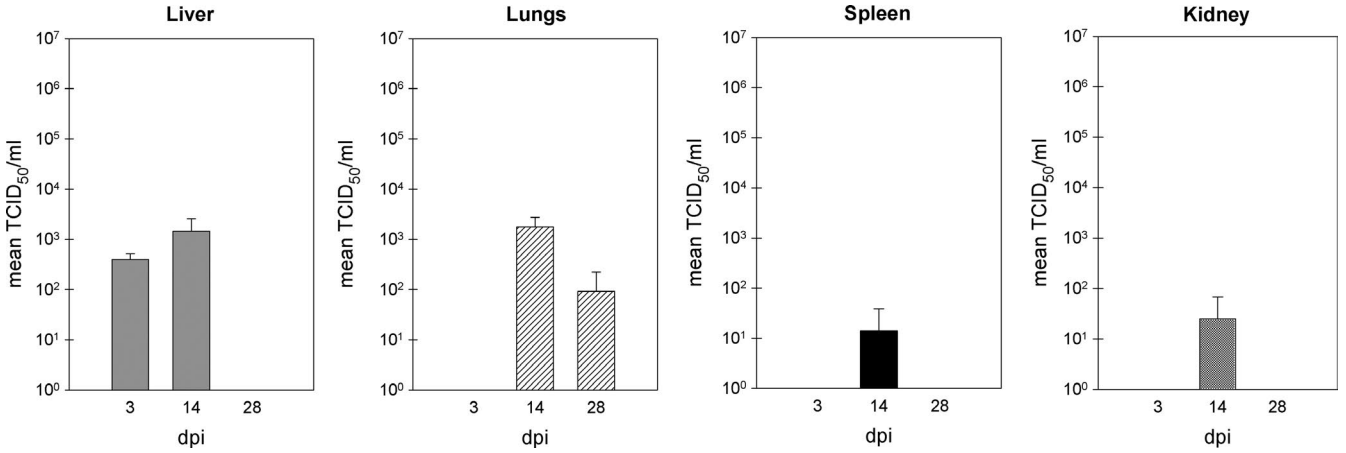

FIGURE 7 Quantification of viral loads. Mean detected viral loads in tissues per dissection day with corresponding standard deviation. Only samples positive by qRT-PCR were analysed. Contact animals are not included

distribution was reached at dpi 14 with 100% of the rats showing focal to multifocal RVFV-positive hepatocytes (Figure 8f), and foamy alveolar macrophages (Figure 8b), as well as 50% of the rats with focal renal RVFV-positive immunoreactions (Figure 8j). There were no immunoreactive positive samples in the RVFV-infected animals at dpi 28 and none in the uninfected contact animals (Figure 8d,h,l).

TABLE 1 Tissues. (A) Quantification of viral loads ($TCID_{50}$/ml). (B) Immunohistochemistry (detection of RVFV NP)

Tissue	*RR1*	*RR2*	*RR3*	*RR4*	*RR5**	*RR6*	*RR7*	*RR8*	*RR9*	*RR10**	*RR11*	*RR12*	*RR13*	*RR14**	*RR15*
(A)															
Liver	562.34	–	316.23	316.23	–	1778	316.23	562.34	3,162	–	–	–	–	–	–
Lungs	–	–	–	–	–	316.23	1,778	1,778	3,162	–	–	–	316.23	–	–
Spleen	–	–	–	–	–	–	–	56.23	–	–	–	–	–	–	–
Kidney	–	–	–	–	–	–	–	100	–	–	–	–	–	–	–
Heart	–	–	–	–	–	–	–	–	–	–	–	–	–	–	–
Brain	–	–	–	–	–	–	–	–	–	–	–	–	–	–	–
Intestine	–	–	–	–	–	–	–	–	–	–	–	–	–	–	–
	dpi 3					dpi 14					dpi 28				
(B)															
Liver	–	–	+	+	–	+	+	++	+	–	–	–	–	–	–
Lungs	–	–	–	–	–	+	+	++	++	–	–	–	–	–	–
Spleen	–	n.d.	n.d.	–	–	–	–	–	–	–	–	–	–	–	–
Kidney	–	–	–	–	–	–	–	+	+	–	–	–	–	–	–
Heart	–	–	–	–	–	–	–	–	–	–	–	–	–	–	–
Brain	–	–	–	–	–	–	–	–	–	–	–	–	–	–	–
Intestine	n.d.	n.d.	n.d.	n.d.	n.d.	n.d.	n.d.	–	–	n.d.	n.d.	n.d.	n.d.	n.d.	n.d.
	dpi 3					dpi 14					dpi 28				

Abbreviations: –, (A) no titre/(B) viral antigen (0); +, focal or oligofocal (1); ++, multifocal (2); n.d., not determined.

*Contact animals.

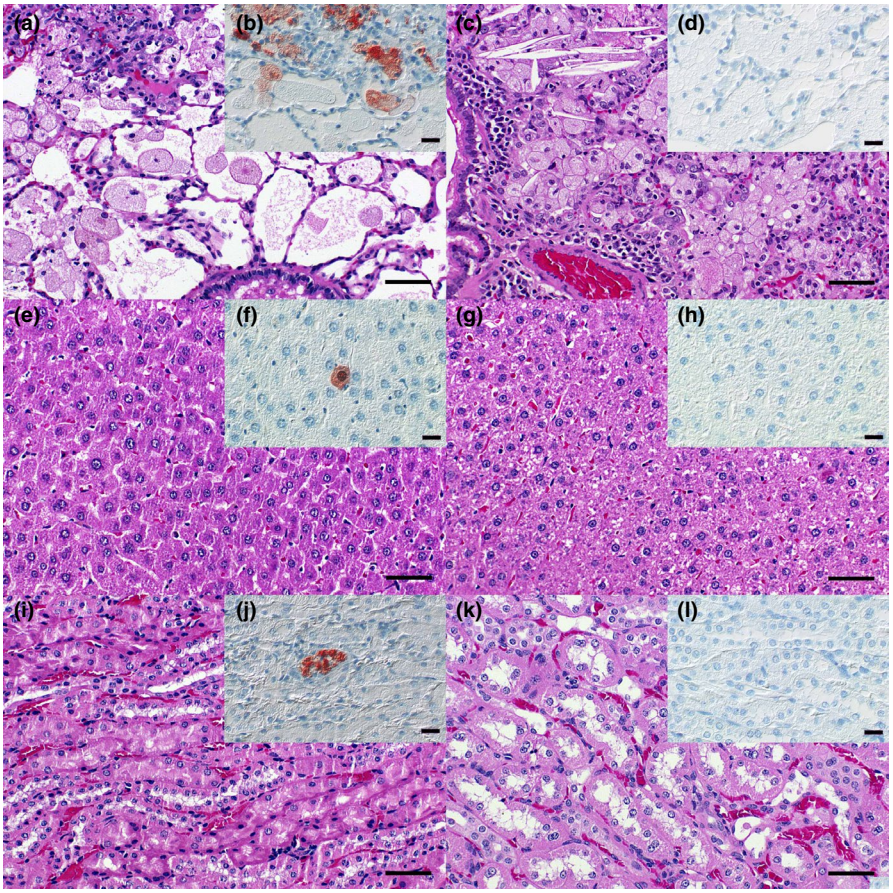

FIGURE 8 Lack of virus-induced histopathological lesions despite immunohistological proof of RVFV NP antigen in (b) alveolar macrophages, (f) hepatocytes and (j) renal tubular epithelia at dpi 14. (a, b, e, f, i, j) *Rattus rattus*. RVFV 35/74, subcutaneous infection, dpi 14. (c, d, g, h, k, l) *Rattus rattus*. Mock-infected negative control, subcutaneous inoculation, dpi 14. (a–d) Lungs. The lungs of the RVFV-infected and the mock-infected rat show a comparable, moderate, multifocal, perivascular, subacute, lymphohistiocytic interstitial pneumonia with alveolar oedema and hyperplasia of foamy alveolar macrophages suggestive of a *Pneumocystis* spp.-induced pulmonary pneumocystosis, which is interpreted as a background lesion. (e–h) Liver. (i–l) Kidney. (a, c, e, g, i, k) Haematoxylin–eosin; bar = 50 μm. (b, d, f, h, j, l) RVFV immunohistochemistry, avidin–biotin–peroxidase complex method including heat-induced epitope retrieval, a polyclonal sheep anti-RVFV MP12-strain NP antiserum (internal number: #SP24; diluted 1:4,000), 3-amino-9-ethylcarbazole as chromogen (red-brown) and haematoxylin counterstain (blue); bar = 20 μm

4 | DISCUSSION

The aim of the study was the evaluation of *Rattus rattus* as possible RVFV reservoir and amplification host and therefore analysing its susceptibility to RVFV and the persistence of the virus. Furthermore, horizontal transmission between black rats was examined. In this study, rats developed a viraemia and RVFV-specific antibodies. As eight out of 12 infected rats also showed evidence of RVFV replication in tissue, it can be concluded that black rats are susceptible to RVFV infection. Despite of this susceptibility, no clinical RVF manifestation was observed in any rat. None of the animals showed changes in weight or behaviour. Consequently, according to *F. Rodhain* (Rodhain, 1998), the necessary characteristics to serve as an amplification host are given in these rats.

The investigation of the immunocompetence of black rats against RVFV revealed IgG generation and the presence of RVFV-neutralizing antibodies from dpi 14. The comparison of antigen-specific immune responses showed highest immune responses to NP, followed by Gn, NSm and the major factor of virulence NSs. This is consistent with previous studies that reported highest antibody reaction against NP and comparable low immune responses to NSs after infection with RVFV (McElroy et al., 2009; Pepin et al., 2010).

Despite the presence of neutralizing antibodies, viraemia lasted for up to 17 days. Replicable RVFV was detected in blood from dpi 4–14, and viral RNA was detected for seven more days (dpi 3–21). The duration of viraemia is comparable to that of highly susceptible ruminants. In sheep, the experimental infection with RVFV 35/74 resulted in viraemia for up to 7 days (Oreshkova et al., 2013) and the presence of viral RNA until dpi 16 was previously described (Kortekaas et al., 2012). A viral load above $10^{4.5}$ plaque-forming units/ml was proposed to be sufficient for RVFV host–mosquito transmission (Golnar et al., 2014). Viral RNA levels in blood of susceptible small ruminants can reach over 10^9 copies/ml (Oreshkova et al., 2013), and titres of up to 10^6 $TCID_{50}$/ml can be detected (Kortekaas et al., 2012). In this study, viraemia of up to 10^4 $TCID_{50}$/ml was found in black rats. Since differences between the loads of viral RNA in serum and blood

cruor samples have been described before (B. Gutjahr & R. König, unpublished data), $TCID_{50}$ values may actually be higher in the circulating blood. We therefore assume that RVFV transmission from black rats to mosquitoes is possible, although viral loads found in this study are below the viral titre previously proposed as required. Other data also indicate that thresholds for virus transmission from animals to mosquitoes differ among different mosquito species and species biotypes (Vloet et al., 2017). The long viremic phase of up to 17 days may result in an increased likelihood of RVFV transmission to mosquitoes, although other studies have shown that transmission from sheep to mosquitoes can only occur during the peak of viraemia (Vloet et al., 2017). In black rats, viraemia peaked between dpi 5 and 7, but at dpi 14 again high amounts of viral RNA were found in blood cruor. Together, these findings demonstrate that further comprehensive experimental infection studies are needed to evaluate RVFV transmission from black rats to different mosquito species.

RVFV RNA was found in all seven examined tissues and in six tissues, it was detected until the last day of the experiment (dpi 28). These results are remarkable compared to those obtained in susceptible small ruminants. In various infection studies, viral RNA was found in kidneys, livers, spleens or brains (Busquets et al., 2010; Miller et al., 2015; Oreshkova et al., 2013; Wilson et al., 2016), but animals are often only positive in some of their tissues and virus can mostly not be found longer than dpi 21 (Busquets et al., 2010; Wilson et al., 2016). The results of this study may indicate RVFV persistence in tissues of black rats, but to gain closer insights, the course of the infection after dpi 28 has to be further investigated. Despite of the high viral RNA amounts detected in tissues, the $TCID_{50}$ assay revealed low viral loads and in hearts, brains and intestines, no replicable virus was found. Other studies have also shown that qRT-PCR is much more sensitive than virus isolation and that virus can only be isolated from samples containing RNA levels higher than 10^5 copies/ml (Kortekaas et al., 2012; Wichgers Schreur et al., 2016). In this study, viral loads could also be quantified in samples with lower levels of viral RNA. Additionally, we found a positive correlation between RNA levels in lungs, livers and kidneys and positive results in the immunohistochemistry (Table 2). Most of the tissue samples with detectable viral loads were also positive in the immunohistochemistry (Table 1). In immunohistochemistry, viral NP was found in livers, lungs and kidneys of animals euthanized at dpi 3 and 14. Despite this evidence of viral replication, no unequivocally virus-induced histopathological lesions were observed in any tissue at any sampling day. These findings suggest virus persistence in tissues of black rats without affecting the animals. They differ markedly from results of RVFV infection studies on susceptible ruminants in which pathological lesions occur in the infected animals (Wichgers Schreur et al., 2016; Wilson et al., 2016). High viral RNA levels until dpi 28 without evidence of illness have not been described in any vertebrate before. Previous experimental studies on in-bred rats revealed different infection pattern in rats, depending on their genetic background. But even rat strains that are less susceptible to RVFV infection than other strains can develop encephalitic lesions (Anderson et al., 1987; Bales et al., 2012). In order to verify whether genetic modifications of the virus led to a loss of pathogenicity, NGS was performed using RNA of the lungs of the rat with the highest viral RNA load. The results revealed that no mutations of the virus occurred in this rat until dpi 14. Therefore, it is possible that the lack of pathogenicity may be due to species-specific characteristics of black rats regarding RVFV infection, but more in-depth studies need to be performed to gain firm knowledge.

Due to its typical manifestation, we suspect the perivascular pneumonia with alveolar oedema and hyperplasia of foamy alveolar macrophages found in the majority of infected, but also of contact and negative control animals, to be caused by a co-existing pulmonary pneumocystosis. As highest RVFV RNA loads were found in the rats' lungs, it is possible that this fungal infection may have affected the course of the viral infection, especially since lungs are not considered target tissue of RVFV (Bales et al., 2012). Infection with *Pneumocystis* spp. has already been found in wildlife *Rattus rattus* (Rothenburger et al., 2015), leading to the assumption that a coinfection of these two pathogens could also occur in nature. More research is needed to evaluate a possible interplay of both pathogens.

Additionally, in black rats, oral, rectal and conjunctival RVFV shedding was observed until the last sampling day (dpi 24). The recurrent evidence of virus shedding again indicates potential RVFV persistence in black rats. However, the occurrence of a horizontal transmission was not observed in contact animals. We assume that the detection of few copies of viral RNA in the intestine of a contact animal (*RR10*) was due to oral RVFV exposure, which did not lead to RVFV replication in the animal, as no other evidence of RVFV infection was found in this rat. Virus shedding has also been shown in susceptible livestock, but nevertheless conflicting data are published concerning the occurrence of horizontal transmission in ruminants (Busquets et al., 2010; Wichgers Schreur et al., 2016). It is likely that the behaviour of wild rats differs from that of rats kept under laboratory conditions and that aggressive behaviour, leading to virus transmission, may occur more frequently in the wild. In addition, human infections via aerosol have been described repeatedly (Hoogstraal et al., 1979). Therefore, RVFV transmission from rats to humans and other vertebrates should remain a concern and be further investigated.

TABLE 2 Correlation between immunohistochemistry and qRT-PCR results in tissues

Tissue	Spearman's rank correlation rho	95% confidence interval	*p*-value
Liver	0.8303	0.5534–0.9419	.0001
Lungs	0.7929	0.4726–0.9282	.0004
Spleen	n.d.	n.d.	n.d.
Kidney	0.6009	0.1281–0.8512	.0178
Heart	n.d.	n.d.	n.d.
Brain	n.d.	n.d.	n.d.
Intestine	n.d.	n.d.	n.d.

Note: Spearman's rank correlation rho: 0 = no correlation, >0 to 1 = positive correlation and <0 to −1 = negative correlation.
Abbreviation: n.d., not determined.

In summary, it can be assumed that black rats are likely to be involved in the transmission cycle of RVFV, but further research is needed to investigate the role of black rats from endemic areas in the virus' maintenance. Experimental studies and field studies during both enzootic and epidemic periods will help to assess the occurrence of an interaction between black rats and RVFV vectors as well as virus transmission from these rats to humans and livestock.

ACKNOWLEDGEMENTS

The authors would like to thank Kristin Vorpahl, Silvia Schuparis, Martina Abs and Birke Böttcher for their excellent technical assistance. We want to thank Markus Keller, Rainer Ulrich and Dania Richter for sharing their expertise on rats. Many thanks to Jana Schulz, Andreas Fröhlich and Susanne Amler for statistical analyses and to Dirk Höper for NGS. Finally, we would like to thank the animal caretakers for their support during the experiment. The authors are very grateful for the DFG (Deutsche Forschungsgemeinschaft, grant number: GR 980/4-1) funding for this study.

CONFLICT OF INTEREST

The authors declare no conflicts of interest.

ETHICAL APPROVAL

The authors confirm that the ethical policies of the journal, as noted on the journal's author guidelines page, have been adhered to. Performance of the experiments was carried out in accordance with national and European legislation (Directive 2010/63/EU). It was approved by the competent authority of the Federal State of Mecklenburg-Western Pomerania, Germany (LALLF, Rostock, Germany; reference number: 7221.3-1-038/18).

ORCID

Martin Eiden https://orcid.org/0000-0002-1197-8288
Martin H. Groschup https://orcid.org/0000-0003-0215-185X

REFERENCES

Anderson, G. W. Jr, Slone, T. W. Jr, & Peters, C. J. (1987). Pathogenesis of Rift Valley fever virus (RVFV) in inbred rats. *Microbial Pathogenesis*, *2*, 283–293. https://doi.org/10.1016/0882-4010(87)90126-4

Bales, J. M., Powell, D. S., Bethel, L. M., Reed, D. S., & Hartman, A. L. (2012). Choice of inbred rat strain impacts lethality and disease course after respiratory infection with Rift Valley Fever Virus. *Frontiers in Cellular and Infection Microbiology*, *2*, 105. https://doi.org/10.3389/fcimb.2012.00105

Balkhy, H. H., & Memish, Z. A. (2003). Rift Valley fever: An uninvited zoonosis in the Arabian peninsula. *International Journal of Antimicrobial Agents*, *21*, 153–157. https://doi.org/10.1016/S0924-8579(02)00295-9

Bird, B. H., Bawiec, D. A., Ksiazek, T. G., Shoemaker, T. R., & Nichol, S. T. (2007). Highly sensitive and broadly reactive quantitative reverse transcription-PCR assay for high-throughput detection of Rift Valley fever virus. *Journal of Clinical Microbiology*, *45*, 3506–3513. https://doi.org/10.1128/JCM.00936-07

Bird, B. H., Ksiazek, T. G., Nichol, S. T., & Maclachlan, N. J. (2009). Rift Valley fever virus. *Journal of the American Veterinary Medical Association*, *234*, 883–893. https://doi.org/10.2460/javma.234.7.883

Busquets, N., Xavier, F., Martin-Folgar, R., Lorenzo, G., Galindo-Cardiel, I., del Val, B. P., Rivas, R., Iglesias, J., Rodriguez, F., Solanes, D., Domingo, M., & Brun, A. (2010). Experimental infection of young adult European breed sheep with Rift Valley fever virus field isolates. *Vector Borne and Zoonotic Diseases*, *10*, 689–696. https://doi.org/10.1089/vbz.2009.0205

Chevalier, V., Pepin, M., Plee, L., & Lancelot, R. (2010). Rift Valley fever–a threat for Europe? *Eurosurveillance Weekly*, *15*, 19506. https://doi.org/10.2807/ese.15.10.19506-en

Daubney, R., & Hudson, J. R. (1931). Enzootic hepatitis of rift valley fever. An undescribed virus disease of sheep cattle and man from East Africa. *Journal of Pathology & Bacteriology*, *34*, 545–579.

Daubney, R., & Hudson, J. R. (1932). Rift Valley fever. *The Lancet*, *219*, 611–612. https://doi.org/10.1016/S0140-6736(01)24634-0

Diagne, M. M., Faye, M., Faye, O., Sow, A., Balique, F., Sembene, M., Granjon, L., Handschumacher, P., Faye, O., Diallo, M., & Sall, A. A. (2017). Emergence of Wesselsbron virus among black rat and humans in Eastern Senegal in 2013. *One Health (Amsterdam, Netherlands)*, *3*, 23–28. https://doi.org/10.1016/j.onehlt.2017.02.001

Digoutte, J. P., & Peters, C. J. (1989). General aspects of the 1987 Rift Valley fever epidemic in Mauritania. *Research in Virology*, *140*, 27–30. https://doi.org/10.1016/S0923-2516(89)80081-0

Freed, I. (1951). Rift valley fever in man, complicated by retinal changes and loss of vision. *South African medical journal =. Suid-Afrikaanse Tydskrif Vir Geneeskunde*, *25*, 930–932.

Golnar, A. J., Turell, M. J., LaBeaud, A. D., Kading, R. C., & Hamer, G. L. (2014). Predicting the mosquito species and vertebrate species involved in the theoretical transmission of Rift Valley fever virus in the United States. *PLoS Neglected Tropical Diseases*, *8*, e3163. https://doi.org/10.1371/journal.pntd.0003163

Gora, D., Yaya, T., Jocelyn, T., Didier, F., Maoulouth, D., Amadou, S., Ruel, T. D., & Gonzalez, J. P. (2000). The potential role of rodents in the enzootic cycle of Rift Valley fever virus in Senegal. *Microbes and Infection*, *2*, 343–346. https://doi.org/10.1016/S1286-4579(00)00334-8

Hoogstraal, H., Meegan, J. M., Khalil, G. M., & Adham, F. K. (1979). The Rift Valley fever epizootic in Egypt 1977–78. 2. Ecological and entomological studies. *Transactions of the Royal Society of Tropical Medicine and Hygiene*, *73*, 624–629.

Imam, I. Z., El-Karamany, R., & Darwish, M. A. (1979). An epidemic of Rift Valley fever in Egypt. 2. Isolation of the virus from animals. *Bulletin of the World Health Organization*, *57*, 441–443.

Jackel, S., Eiden, M., El Mamy, B. O., Isselmou, K., Vina-Rodriguez, A., Doumbia, B., & Groschup, M. H. (2013). Molecular and serological studies on the Rift Valley fever outbreak in Mauritania in 2010. *Transboundary and Emerging Diseases*, *60*(Suppl 2), 31–39. https://doi.org/10.1111/tbed.12142

Kärber, G. (1931). Beitrag zur kollektiven Behandlung pharmakologischer Reihenversuche. *Archiv Für Experimentelle Pathologie Und Pharmakologie*, *162*, 480–483. https://doi.org/10.1007/BF01863914

Kortekaas, J., Antonis, A. F., Kant, J., Vloet, R. P., Vogel, A., Oreshkova, N., de Boer, S. M., Bosch, B. J., & Moormann, R. J. (2012). Efficacy of three candidate Rift Valley fever vaccines in sheep. *Vaccine*, *30*, 3423–3429. https://doi.org/10.1016/j.vaccine.2012.03.027

Linthicum, K. J., Britch, S. C., & Anyamba, A. (2016). Rift Valley fever: An emerging mosquito-borne disease. *Annual Review of Entomology*, *61*, 395–415. https://doi.org/10.1146/annurev-ento-010715-023819

Lutomiah, J., Omondi, D., Masiga, D., Mutai, C., Mireji, P. O., Ongus, J., Linthicum, K. J., & Sang, R. (2014). Blood meal analysis and virus detection in blood-fed mosquitoes collected during the 2006–2007 Rift Valley fever outbreak in Kenya. *Vector Borne and Zoonotic Diseases*, *14*, 656–664. https://doi.org/10.1089/vbz.2013.1564

McElroy, A. K., Albarino, C. G., & Nichol, S. T. (2009). Development of a RVFV ELISA that can distinguish infected from vaccinated animals. *Virology Journal*, *6*, 125. https://doi.org/10.1186/1743-422X-6-125

Meegan, J. M., Hoogstraal, H., & Moussa, M. I. (1979). An epizootic of Rift Valley fever in Egypt in 1977. *The Veterinary Record*, *105*, 124–125. https://doi.org/10.1136/vr.105.6.124

Miller, M. M., Bennett, K. E., Drolet, B. S., Lindsay, R., Mecham, J. O., Reeves, W. K., Weingartl, H. M., & Wilson, W. C. (2015). Evaluation of the efficacy, potential for vector transmission, and duration of immunity of MP-12, an attenuated rift valley fever virus vaccine candidate, in sheep. *Clinical and Vaccine Immunology: CVI*, *22*, 930–937. https://doi.org/10.1128/CVI.00114-15

Ninove, L., Nougairede, A., Gazin, C., Thirion, L., Delogu, I., Zandotti, C., Charrel, R. N., & De Lamballerie, X. (2011). RNA and DNA bacteriophages as molecular diagnosis controls in clinical virology: A comprehensive study of more than 45,000 routine PCR tests. *PLoS ONE*, *6*, e16142. https://doi.org/10.1371/journal.pone.0016142

OIE World Organisation for Animal Health. (2012). *Manual of diagnostic tests and vaccines for terrestrial animals (Terrestrial Manual). Chapter 2.1.14*.

OIE World Organisation for Animal Health. (2018). *Manual of Diagnostic Tests and Vaccines for Terrestrial Animals (Terrestrial Manual). Chapter 3.1.18*.

Olive, M. M., Goodman, S. M., & Reynes, J. M. (2012). The role of wild mammals in the maintenance of Rift Valley fever virus. *Journal of Wildlife Diseases*, *48*, 241–266. https://doi.org/10.7589/0090-3558-48.2.241

Oreshkova, N., van Keulen, L., Kant, J., Moormann, R. J., & Kortekaas, J. (2013). A single vaccination with an improved nonspreading Rift Valley fever virus vaccine provides sterile immunity in lambs. *PLoS ONE*, *8*, e77461. https://doi.org/10.1371/journal.pone.0077461

Pepin, M., Bouloy, M., Bird, B. H., Kemp, A., & Paweska, J. (2010). Rift Valley fever virus(Bunyaviridae: Phlebovirus): An update on pathogenesis, molecular epidemiology, vectors, diagnostics and prevention. *Veterinary Research*, *41*, 61.

Peters, C. J., & Slone, T. W. (1982). Inbred rat strains mimic the disparate human response to Rift Valley fever virus infection. *Journal of Medical Virology*, *10*, 45–54. https://doi.org/10.1002/jmv.1890100107

Rissmann, M., Stoek, F., Pickin, M. J., & Groschup, M. H. (2019). Mechanisms of inter-epidemic maintenance of Rift Valley fever phlebovirus. *Antiviral Research*, *104692*. https://doi.org/10.1016/j.antiviral.2019.104692

Ritter, M., Bouloy, M., Vialat, P., Janzen, C., Haller, O., & Frese, M. (2000). Resistance to Rift Valley fever virus in Rattus norvegicus: Genetic variability within certain 'inbred' strains. *The Journal of General Virology*, *81*, 2683–2688. https://doi.org/10.1099/0022-1317-81-11-2683

Rodhain, F. (1998). The idea of natural reservoir in arbovirology. *Bulletin De La Societe De Pathologie Exotique*, *1990*(91), 279–282.

Rothenburger, J. L., Himsworth, C. G., Clifford, C. B., Ellis, J., Treuting, P. M., & Leighton, F. A. (2015). Respiratory pathology and pathogens in Wild Urban Rats (Rattus norvegicus and Rattus rattus). *Veterinary Pathology*, *52*, 1210–1219.

Vloet, R. P. M., Vogels, C. B. F., Koenraadt, C. J. M., Pijlman, G. P., Eiden, M., Gonzales, J. L., van Keulen, L. J. M., Wichgers Schreur, P. J., & Kortekaas, J. (2017). Transmission of Rift Valley fever virus from European-breed lambs to Culex pipiens mosquitoes. *PLoS Neglected Tropical Diseases*, *11*, e0006145. https://doi.org/10.1371/journal.pntd.0006145

Wichgers Schreur, P. J., van Keulen, L., Kant, J., Oreshkova, N., Moormann, R. J., & Kortekaas, J. (2016). Co-housing of Rift Valley Fever Virus Infected Lambs with Immunocompetent or Immunosuppressed Lambs Does Not Result in Virus Transmission. *Frontiers in Microbiology*, *7*, 287. https://doi.org/10.3389/fmicb.2016.00287

Wilson, W. C., Davis, A. S., Gaudreault, N. N., Faburay, B., Trujillo, J. D., Shivanna, V., Sunwoo, S. Y., Balogh, A., Endalew, A., Ma, W., Drolet, B. S., Ruder, M. G., Morozov, I., McVey, D. S., & Richt, J. A. (2016). Experimental infection of calves by two genetically-distinct strains of Rift Valley fever virus. *Viruses*, *8*(5), 145. https://doi.org/10.3390/v8050145

Wylezich, C., Papa, A., Beer, M., & Hoper, D. (2018). A Versatile Sample Processing Workflow for Metagenomic Pathogen Detection. *Scientific Reports*, *8*, 13108. https://doi.org/10.1038/s41598-018-31496-1

Youssef, B. Z., & Donia, H. A. (2001). The potential role of Rattus rattus in enzootic cycle of Rift Valley Fever in Egypt. 1-Detection of RVF antibodies in R. rattus blood samples by both enzyme linked immuno sorbent assay (ELISA) and immuno-diffusion technique (ID). *The Journal of the Egyptian Public Health Association*, *76*, 431–441.

Youssef, B. Z., & Donia, H. A. (2002). The potential role of rattus rattus in enzootic cycle of Rift Valley Fever in Egypt 2-application of reverse transcriptase polymerase chain reaction (RT-PCR) in blood samples of Rattus rattus. *The Journal of the Egyptian Public Health Association*, *77*, 133–141.

SUPPORTING INFORMATION

Additional supporting information may be found online in the Supporting Information section.

How to cite this article: Stoek F, Rissmann M, Ulrich R, Eiden M, Groschup MH. Black rats (*Rattus rattus*) as potential reservoir hosts for Rift Valley fever phlebovirus: Experimental infection results in viral replication and shedding without clinical manifestation. *Transbound Emerg Dis*. 2022;69:1307–1318. https://doi.org/10.1111/tbed.14093